

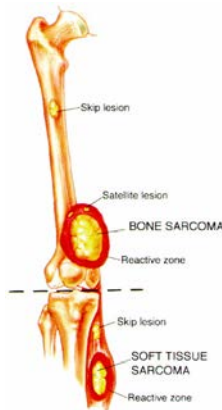# Swiss National Sarcoma Advisory Board

## SURGICAL SARCOMA GUIDELINES

### Introduction

Surgery is the mainstay of sarcoma treatment. The biopsy has to be orchestrated with the final surgery. The goal of surgery is to obtain wide margins, which leaves a cuff of normal tissues around the tumor. The appropriately trained sarcoma surgeon understands that optimal results can only be achieved interdisciplinarily after defining the treatment strategy at a Sarcoma Board.

It is crucial to respect the underlying biology of sarcomas to obtain optimal treatment results:



**Growth:** Sarcomas usually grow centripetally (they push, they may not infiltrate such as carcinomas), with the most immature part at the leading edge.

**Reactive zone:** tissue between tumor and surrounding normal tissue, includes proliferation of mesenchymal and inflammatory cells, neovasculature, and satellite cells.

**Satellite lesion:** these are cellular tumor (micro-)nodules and/or microextensions of the tumor.

**Skip lesion:** cellular tumor nodules outside the reactive zone, but within the compartment.

1.) Ideally, the same person/team who performs the biopsy is also performing definitive surgery so that the biopsy tract lies within the line of definitive resection.

2.) Indications to perform a biopsy (always after complete local imaging):

- for each subfascial (underneath the fascia) lesion
- superficial (epifascial) lesion >3-5cm (exception: classic lipoma)
- whenever there is suspicion (incl. low on T1, high on T2)
- always after complete local imaging

3.) Types of biopsies

- fine needle biopsy
  - rare exception – not recommended as routine.
- tru-cut / trocar biopsy (CT- or US-imaging guided)
  - is used whenever possible, in close collaboration with radiologist/pathologist
  - preferred technique in most sarcoma centers
  - lesions above 2 cm
- incisional biopsy
  - rarely used
  - after failures / non diagnostic results using techniques above
  - always longitudinal, never horizontal
  - larger tissue quantities for molecular studies is no indication
  - smallest possible length
  - meticulous hemostasis (after release of tourniquet)
  - liberal use thrombostatic material (soft tissue) or cement (bone) if necessary
  - if drainage is used, place it in line to the incision closely to or in the corner of the wound.
  - deliberate use of post-biopsy compressive dressing

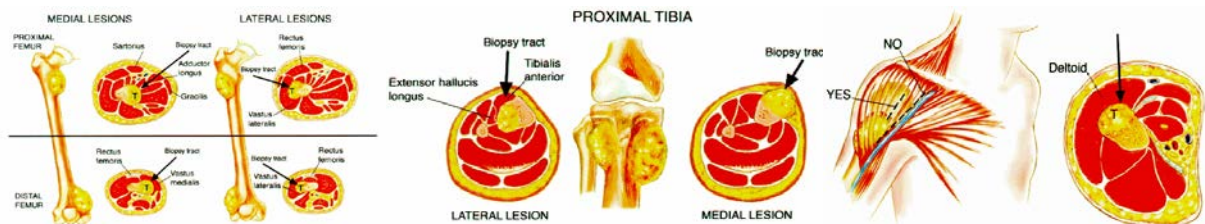
# Swiss National Sarcoma Advisory Board

## SURGICAL SARCOMA GUIDELINES

- use imaging to document biopsy location (particularly bone tumors)
- provide your pathologist with all important clinical information and imaging
- excisional biopsy
  - only used when lesion <2cm (please mark orientation!)

### Pearls:

- All biopsy tracts should lie within the planned surgical excision at definitive surgery.
- always use as direct approach to the tumor as possible.
- always keep a distance to nerves and major vessel if these are not planned to be removed during tumor resection → do not contaminate uninvolved tissues planes or compartments.
- consider different diagnoses including worst case scenario in your strategic biopsy planning in light of definitive surgical resection with wide margins.
- in the posterior gluteal region, an oblique incision which parallels the gluteus maximus fibers may be considered.
- tattooing of biopsy on skin may be considered
- Don't forget to take samples for microbiology if an infection cannot be excluded!



#### 4.) Definition of treatment strategy at regional Sarcoma Board/Center prior to embarking on any treatment is mandatory for all sarcoma patients!

- The assumption “to perform surgery first and then send the patient off” is completely wrong and has to be avoided. Surgery for STS and bone sarcomas needs to be orchestrated with radio-oncology or chemotherapy (induction therapy, adjuvant therapy) to achieve optimal results. Further, not every sarcoma is a sarcoma: think of the underlying biology and adapt your approach.

#### 5.) Definition of Margins

- to determine the margin, a close exchange between sarcoma surgeon and pathologist is mandatory, to orient the specimen.
- the optimal margin is not defined purely by a metric distance, but mainly depends on a.) the histological *sarcoma subtype* with its associated specific biology, b.) the (success of) *preoperative treatment*, and c.) *anatomic barriers*.

##### a.) histological subtype:

There are some sarcoma subtypes which are locally more aggressive than others (myxofibrosarcoma, angiosarcoma, desmoid, DFSP). The sarcoma surgeon must understand the underlying biology and may therefore consider widerer safety margins than usual.

# Swiss National Sarcoma Advisory Board

## SURGICAL SARCOMA GUIDELINES

b.) preoperative (neoadjuvant / induction) treatment:

\* Radiation Therapy (RT)

1.) aim/benefit of RT combined with surgery: RT eliminates satellite cells, and taking biological barriers into account, allows more often/better preservation of critical structures, thereby improving function.

2.) RT sequence: differences between preop- vs postoperative RT for STS:

-same oncological outcome

-preop RT: less radiation dosage, less radiation volume, therefore less side effects

3.) technical RT approach: intensity modulated RT (IMRT) vs conventional conformal three-dimensional RT (3D):

-generally: IMRT decreases wound healing complications by its potential to better spare normal tissues outside the planning target volume (PTV) –e.g. skin not to be included in the PTV; skin sparing is a substantial key parameter regarding wound healing (please note: IMRT spares normal tissue in most, not in all cases; if benefit unclear/doubtful in individual case: comparative planning indicated!)

\* Chemotherapy (and bone sarcomas):

considering the biology of the tumor is key! Comparison of pre- versus post-treatment MRI imaging allows definition of surgical margins. If the chemotherapy response rate is >95%, margins are less crucial; this is in stark contrast to margins with non-responders.

→ be aware of skip lesions and of extraosseous extensions of the tumor.

c.) Evaluation of biological barriers (in conjunction with preoperative therapy):

Definition: a biological barrier is any (relative) resistance against tumor invasion

thick barrier: iliotibial band, presacral fascia, joint capsule, periosteum of child

thin barrier: muscle fascia, periosteum of adult, vessel sheath, epineurium, growth plate.

-if barrier is not infiltrated:

tumor is removed with barrier

-if tumor is infiltrating barrier:

en bloc removal with tumor

-if there is no barrier:

as much margin as possible (longitudinally 3-5cm, radially 1cm)

→ Conclusion regarding margin & sarcoma surgery:

the goal of surgical treatment is an R0/wide resection with good functional outcome!

- Soft tissue sarcomas:

R0: surgical margins are macro- and microscopically negative

R1: surgical margin microscopically contaminated with tumor cells, or the tumor was marginally resected along tumor pseudocapsule.

R2: intralesional tumor resection, with macroscopic tumor left

# Swiss National Sarcoma Advisory Board

## **SURGICAL SARCOMA GUIDELINES**

- Bone sarcomas:

Compartmental: removal of the entire bone and/or its compartment

Wide: a cuff of normal tissue (can be from 2-5cm)

Marginal: through reactive zone, keeps tumor capsule intact

Intralesional: through the tumor

6.) Should there be any sarcoma surgery related question, please feel free to contact your sarcoma surgeon at your regional Sarcoma Center.

7.) Last but not least:

The resection of particularly soft tissue sarcomas concerns all surgical disciplines. These guidelines are intended to help in the everyday situation and should not represent legal constraint despite high level of evidence.

**Inaugurated at the 2<sup>nd</sup> Swiss National Sarcoma Advisory Board Meeting in Zurich on March 27, 2014**